& Clinical Studies

Experience

Clinical Book
Articles & Publications
Preview

Marouene Ben Hadj Hassine - Paolo Bucci - Roberta Gasparro - Alessandro Espedito Gilberto Sammartino - Enguerran Lyautey - David Mailhes - Pantaleo Giuseppe Nuzzolo Paolo - Amato Massimo - Francesco Riccitiello - Bernard Chapotat - Eric Schneck - Vincenzo Cerone - Oreste Trosin - Alberto Maltagliati - Andrea Ottonello Giulio Raffaghello - Andrea Mascolo - Giovanni Falisi - Massimo Galli - Pedro Vittorini Velasquez - Juan Carlos Gallegos Rivera - Roberto Minasi - Alberto De Biase - Carlo Di Paolo - Olivier Granjon - Enzo Di Iorio - Marco Berardini - Alain Simonpieri - Stephan Fraisier - Gilles Montalbot - Caroline Bolle - Marie-Paule Gustin - Didier Fau - Patrick Exbrayat - Georges Boivin - Brigitte Grosgogeat - Marco Esposito - Carlo Barausse Roberto Pistilli - Vittorio Checchi - Michele Diazzi - Maria Rosaria Gatto - Pietro Felice

Global D
Partenaire de vos chirurgies

SOMMAIRE

In-Kone® & EVL®

twinkon®

In-Kone® & EVL®

Safe approcah in "all-on-four" technique: a case report

Marouene Ben Hadj Hassine, DDS
Paolo Bucci, MD, DDS
Roberta Gasparro, DDS, PhD
Alessandro Espedito Di Lauro, DDS
Gilberto Sammartino, MD, DDS

Annali di Stomatologia 2014;V(4):142-145

The "All-on-Four" concept is based on the placement of four implants in the anterior part of fully edentulous jaws to support a provisional, fixed and immediately loaded full-arch prosthesis. Combining tilted and straight implants for supporting fixed prostheses can be considered a viable treatment modality resulting in a more simple and less time consuming procedure, in significantly less morbidity, in decreased financial costs and a more comfortable postsurgical period for the patients. The authors present a case report with mandibular atrophy and left mental foramina on the top of the residual crest.

Keywords: edentulous jaw, dental implants, implant placement

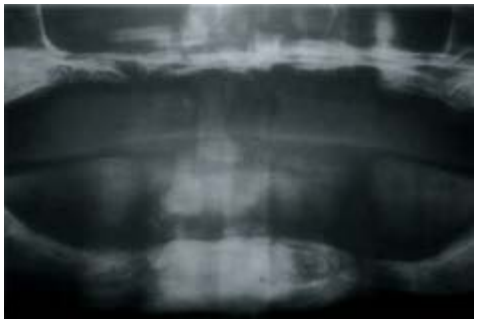

Preoperative panoramic radiograph

Implants et édentement complet mandibulaire

Enguerran Lyautey

Implant 2015;21 :51-57

Le traitement de l'édenté complet mandibulaire a connu de nombreuses évolutions au cours des dernières décennies et les possibilités actuelles de traitement vont de la simple stabilisation par deux implants d'une prothèse amovible à la réalisation de prothèses fixes ostéo-ancrées. Si, dans la majorité des cas, la symphyse mentonnière offre un volume osseux compatible avec la mise en place d'implants dentaires, il est parfois nécessaire, dans certains cas d'atrophie sévère, de réaliser des augmentations osseuses.

Le cas clinique présenté dans cet article montre qu'il peut parfois exister des solutions simples pour réaliser des greffes osseuses autogènes volumineuses sans obligatoirement avoir recours aux prélèvements extra-oraux.

Mots clés: mandibule, greffe osseuse, implant, barre

Radiographie panoramique après implantation

Mise en place de la barre usinée

Le positionnement sous-cortical

Partie I. Considérations biologiques

David Mailhes

Implant 2014;20:335-340

L'ostéo-intégration des implants en alliage de titane, quelles que soient leurs caractéristiques, est aujourd'hui un processus fiable et reproductible. L'objectif de l'implantologie moderne paraît désormais devoir être la pérennité des constructions implanto-portées, tant sur le plan fonctionnel qu'esthétique. Dans cette optique, le choix du système implantaire et celui de la technique de pose semblent être des paramètres importants à considérer dans le cadre d'une stratégie de prévention face au risque de péri-implantite. Nous présentons dans cette première partie les raisons qui nous ont conduit à choisir de placer les implants dans une position sous-crestale au-delà de l'os cortical, donc une position sous-corticale. Dans une seconde partie à paraître, nous détaillerons un protocole clinique simple et original permettant de sécuriser le positionnement sous-cortical des implants.

Mots clés : sous-crestal, sous-cortical, platform switching, vascularisation, esthétique

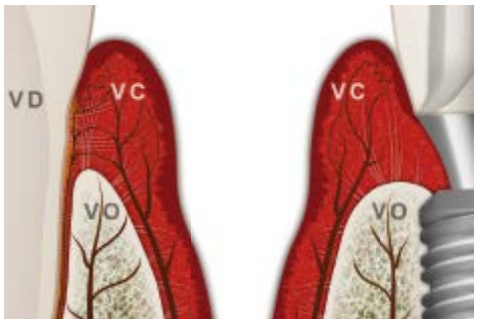

Vascularisation osseuse (VO), Vascularisation conjonctive (VC)
Et vascularisation desmodontale (VD

Partie II. Protocole chirurgical

Implant 2015;21:25-32

Dans une précédente publication, nous avons exposé et analysé les considérations biologiques qui ont guidé notre choix de système implantaire et de positionnement sous-cortical des implants. Cette seconde partie détaille les notions fondamentales qui ont conduit à l'élaboration du protocole opératoire qui est utilisé de façon systématique dans notre activité clinique. Ce protocole est présenté ici en trois phases. La phase chirurgicale introduit la séquence de forage du nouveau protocole ULTIMATE (Global D), et en propose une utilisation personnalisée afin de sécuriser un positionnement sous-cortical des implants, à 3 mm en sous-crestal.

Mots clés: mandibule, greffe osseuse, implant, barre

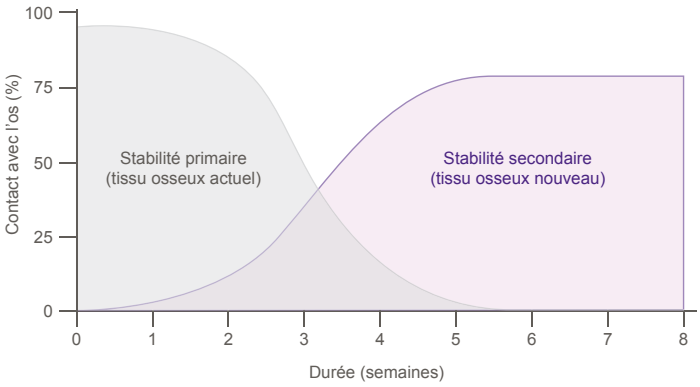

Minimally invasive approaches to optimize block grafting: a case report

Gilberto Sammartino, Giuseppe Pantaleo, Paolo Nuzzolo, Massimo Amato, Francesco Riccitiello.

J Oral Implantol. 2014 Sep 18

In narrow alveolar ridge many surgical approaches exist, and the most frequently used is bone grafting. The sub-periosteal tunneling approach is a minimal safety procedure that allows to allocate the graft in a space that is obtained between the soft tissues and the underlying bone, through an access represented by one single incision on the mesial limit of the bone defect.
A 55-year-old caucasian woman with a severe bone atrophy in the maxillary arch was treated with horizontal bone augmentation. A muco-periosteal tunnel with a periosteal elevator through one single incision of moderate dimensions per hemi-arch, insertion of tissue bank ilium bi-cortical bone (FFB) and a consequent complete prosthetic-implant rehabilitation was realized. The tunnel technique provided primary intention closure of the surgical wound, avoiding dehiscences and infections, and reducing the edema and the post-operative discomfort for the patient.
Clinical and histological studies support the use of FFB and it has been suggested that the results of a graft with homologous and with autologous bone can be comparable, even though the healing phase is more critical and longer for the allograft. The combination of homologous grafts with the tunnel technique reduces significantly the surgical trauma and the postoperative discomfort, as well as the risk of exposure of the graft during the healing phase, with the risk of graft failure. In our experience, onlay grafting with frozen bone is a predictable technique for horizontal augmentation.

Keywords : tunnel technique, block grafting, bone augmentation, fresh frozen bone, PRF

Restauration d'un maxillaire avec greffe et d'une mandibule avec implants courts

Bernard Chapotat, Eric Schneck

Implant 2014 ;20: 280-285

Lors de reconstructions implanto-prothétiques, il arrive souvent que le volume osseux ne soit pas satisfaisant. Pour le restaurer, en réalisant le meilleur choix thérapeutique, il est nécessaire de bien considérer les indications et de maîtriser les techniques de reconstruction (ROG ou greffes à l'aide d'os pariétal, iliaque, rétromolaire, allogénique, etc.) ou encore utiliser des implants courts devenus une indication thérapeutique avérée.

Mots clés : comblement sinusien, greffe osseuse, implant court

L'examen radiologique montre une image radioclaire au niveau de 13 et 12 et des pertes d'attache importantes au niveau des dents 14 et 25. Les sinus maxillaires sont proéminents

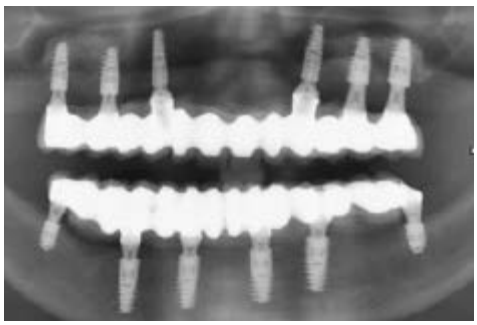

Radiographie à 2 ans postopératoire. Implants In-Kone®

The Platform Switching Approach to Optimize Split Crest Technique. Case report

Gilberto Sammartino, Vincenzo Cerone, Roberta Gasparro, Francesco Riccitiello, Oreste Trosino
Case Rep Dent. 2014; 2014: 850470.
Published online 2014 Aug 6. doi: 10.1155/2014/850470

Implant rehabilitation of edentulous sites with bone atrophy represents a situation in which dental implant placement might be complex or impossible if regeneration and bone augmentation techniques are not used. One of the these techniques is ERE, introduced by Tatum and subsequently modified by Scipioni et al.
This procedure is mainly indicated in cases with sufficient bone height but inadequate thickness. Anyway at least 2-3 mm of initial crestal width is mandatory to perform this technique.
ERE can be followed by simultaneous implant placement in order to maintain the created space. This space can be filled with autologous/heterologous graft, with biomaterials or leaving the clot stabilized by a membrane, with or without the application of platelets concentrates such as PRP or PRF that seems to accelerate the healing of hard and soft tissues.
ERE surgical approach is a reliable technique but does not prevent the peri-implant bone resorption.
Different studies have evaluated the peri-implant bone resorption after implant positioning with ERE technique. Strietzel et al. report that 6 months after functional loading the marginal bone around the implants was reduced on average by 1 mm. In another study, during the same period of observation, the mean bone loss was 2 mm. Jensen et al. reported an average of resorption of 1.57 mm (mesial side) and 1.42 mm (distal side) during an average 4.2 years.
This case shows the absence of bone resorption and a slight bone apposition above the implant in a split crest technique using platform switching associated with Morse-cone connection.

Keywords: edentulous, bone augmentation techniques, dental implants

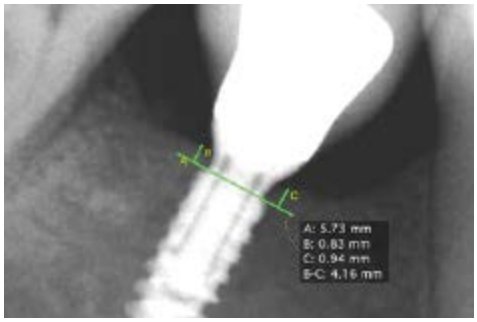

One-year radiographic follow-up

Early loading versus immediate loading: case examples

Alberto Maltagliati, Andrea Ottonello, Giulio Raffaghello, Andrea Mascolo

Implant practice; vol.6 Number 1: 40-43

"Immediate loading" is a favorite way to maintain appropriate anatomic and topographic proportions between dental arches, to maintain the contact with periodontal tissues, and for the "occlusal/ contact memory".1-2 An edentulous area that remains this way for a long period of time may modify and even preclude the possibility of recreating an occlusion that is esthetic, functional, always predictable, and similar to the original.3 The concept of "primary stability," torque wrench, osseointegration, and adequate/suitable denture, are the fundamental factors for immediate and long-distance clinical results.4-5 With immediate loading, the management of peri-implant soft tissues can lead to a long-term predictability with 30-year old case-studies;6-7 moreover, the waiting time for osseointegration allows for modulation/mediation of some human mistakes not managed in the early loading phases in the 72-hour prosthetic technique.8 The use of autologous fibrin glue in the same surgery increases the neoangiogenesis and the healing factors' activity, also obtaining a better predictability regarding soft-tissue management.

Keywords: immediate loading, soft tissue

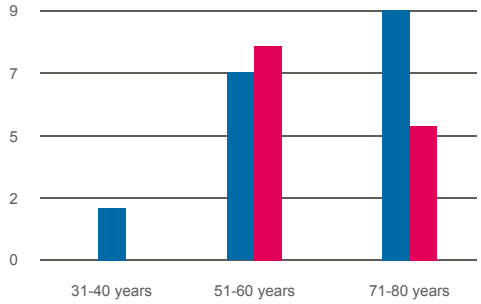

Table 1

	Male	Female	Part. edent	Tot. edent
Early loading	8	10	8	10
Immediate loading	7	6	5	8
Total	15	16	13	18

Table 2

	No disease	Infectioud disease	Heart disease	Diabetes
Early loading	12	2	3	1
Immediate loading	11	0	2	0
Total	23	2	5	1

Table 3

Use of 3D cartilage scaffolds for the stabilization of implants and bone regeneration with the fit-lock technique

Giovanni Falisi, Massimo Galli, Pedro Vittorini-Velasquez, Juan C. Gallegos-Rivera, Roberto Minasi, Alberto De Biase, Carlo Di Paolo

Acta. Odontol. Latinamo. Vol.26 N°3;2013: 167-172

The surgical procedures for implant applications on the lateral upper areas depend on sinus pneumatization and availability of the residual bone.
In these cases, autologous bone grafting remains the gold standard. Nevertheless, because of the morbidity associated to the donor site and the post-surgical complications, several alternative bone substitutes have been introduced, which, however, imply additional costs and show limited osteoinductive properties.
Such limitations can be compensated with new regeneration strategies for biological and mechanical tissue restoration, a subject which has been addressed by tissue engineering in recent years.
The authors present a new therapeutic option for implant application in the upper maxilla with bone availability less than 4 mm by using 3D scaffolds obtained from antigen-free porcine cartilage in the fit-lock technique.
A longitudinal study on 18 consecutive cases was performed, with a 95.2% success rate one year after the implant. The advantages of this new technique are: 1)Functional and anatomical recovery of the maxillary antrum, 2) Immediate application of the implants; 3) Reduction of surgical times; 4) Absence of patient morbidity; 5)Local anesthesia; 6) Use of implants with a diameter > 4 mm.

Keywords : bone regeneration, dental implants

Implant stability evaluation by resonance frequency analysis in the fit lock technique. A clinical study

Giovanni Falisi DDS, PhD
Massimo Galli, MDS
Pedro Vittorino Velasquez, MDS
Juan Carlos Gallegos Rivera, DDS
Carlo Di Paolo, MDS

Annali di Stomatologia 2013;IV(2):196-203

Surgical procedures for the application of implants in the lateral-superior sectors are affected by the availability of the residual bone.
When this condition is lower than 5 mm it is recommended that techniques involving two therapeutic phases, a reconstructive and an applicative one, as reported in the international literature, are adopted. The authors propose here a new method with the potential to apply implants simultaneously with the reconstructive phase.
The aim of this longitudinal retrospective study was to evaluate the stability of implants applied with the fit lock technique in the upper maxillary in us with bone availability lower than 4 mm by measuring resonance frequency at different follow-up periods. The seme as urements, carried out on 30 implants, were analysed with specific statistical procedures.
The results indicate that the stability of the implants inserted with the fit lock method increases progressively over time in a statistically significant manner. The stability recorded after one year from the insertion (ISQ T2) is significantly higher than that recorded after six months (ISQ T1), and this is significantly higher that than recorded at the time of implant placement (ISQ T0).
The implant inserted in the maxillary zones with scarce bone availability and applied with this technique showed a similar stability as reported with other techniques.
In light of the results, the authors confirm that the primary stability represents the basic requirement to guarantee a correct healing of the implant and demonstrate that the fit lock technique also all ows reaching this condition when bone availability is minimal.

Keywords : resonance frequency analysis, bone grafting, dental implants

Elevation du plancher du sinus et pose simultanée d'implants sans utilisation de substituts osseux

Olivier Granjon

Implant 2013; 19 :205-214

Lors d'un édentement postérieur au maxillaire, la présence de la cavité sinusienne associée à la résorption osseuse postextractionelle limite le volume osseux disponible dans ce secteur. La pose d'implants selon un protocole conventionnel est très souvent impossible, une élévation du plancher sinusien est alors nécessaire. Cet article décrit un protocole chirurgical avec abord latéral permettant de réaliser une augmentation du volume sous-sinusien et la mise en place des implants dans le même temps opératoire sans recours à un matériau de comblement.

Mots clés : implant, élévation du plancher sinusien

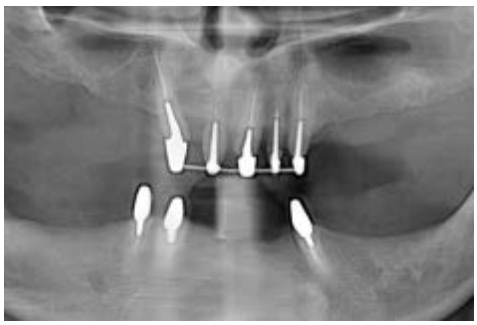

radio panoramique initiale

Place croissante des implants courts et ultracourts dans la thérapeutique implantaire

Eric Schneck, Bernard Chapotat

Implant 2013; 19 :171-179

L'ensemble de la littérature médicale montre que si le seul but des reconstructions osseuses est de mettre en place un implant plutôt long, il est toutefois préférable d'utiliser un implant court si l'esthétique n'intervient pas dans le choix du traitement. L'utilisation d'implants courts (8,5 mm) ou ultracourts (6 mm, voire 4 mm) dans les zones postérieures semble être une bonne solution de remplacement aux reconstructions osseuses mais leur mise en place et leur maintenance demandent une plus grande courbe d'apprentissage que celle des implants longs.

Mots clés : implants courts, implants ultracourts, greffes osseuses, rapport couronne/implant

Use of platform-switched implants with internal conical anti-rotational connection in single-tooth implant replacement

Enzo Di Iorio, Marco Berardini

Dental Camos 2013;81(7):138-145
Utilizzo di impianti a connessione interna conica antirotazionale con platform switching integrato nella riabilitazione implantoprotesica delle monoedentulie

Materials and methods. 15 cases of monoedentulism were rehabilitated using Universal In-Kone® dental implants (Tekka, Brignais, France) which had internal conical connection, and platform-switching design. Implants were placed 1.5 mm below the alveolar ridge. Periapical radiographs were taken before and after surgical and prosthetic procedures. One year after the occlusal load the following clinical parameters were evaluated by the authors: marginal bone loss, plaque index, peri-implant probing depth, suppuration on probing, bleeding on probing, mechanical complications.
Results. No marginal bone losses were observed. Mechanical or biological complications, or reinfections did not occur in any case.
Conclusions. The cases presented show how the use of internal conical anti-rotational connection and platform-switched implants allows implant marginal bone preservation. Biological or mechanical complications, due to bacterial colonization within the gap between fixture and abutment, with this type of connection were also avoided.

Keywords: dental implants, internal conical connection, platform switching, implant-supported rehabilitation, monoedentulism

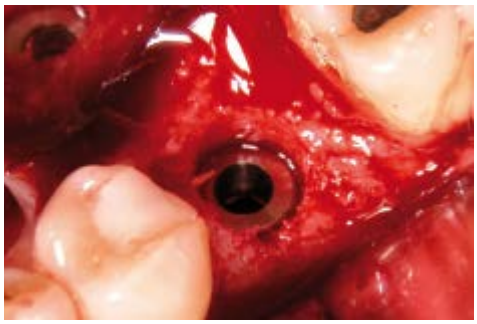

implant placed at bone leve

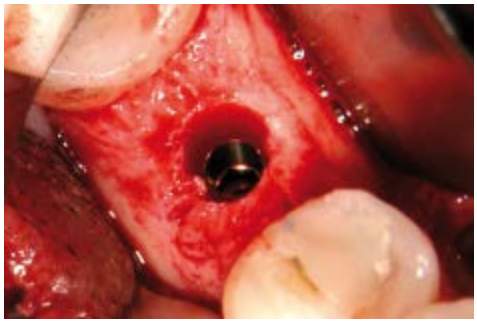

implant placed at 2 mm subcrestal

Positionnement sous-crestal : l'art et la manière d'intensifer le volume des tissus péri-implantaires

Alain Simonpieri

Implant 2013; 19 :127-137

Dans l'implantologie moderne, la gestion optimisée des volumes de tissus péri-implantaires fait partie des sujets d'actualité avec pour objectif l'établissement de plans de traitement permettant l'obtention de résultats de plus en plus esthétiques, prévisibles, reproductibles et aussi pérennes que possible.
Avec l'amélioration quotidienne de la compréhension de notre exercice, on constate une certaine convergence des discours vers un consensus de facteurs clés. Aussi, le postulat « moins de métal et plus de tissus » se profile comme le nouveau paradigme de la discipline.
Celui-ci s'inscrit dans l'adoption d'une approche toujours moins invasive en faveur de la préservation de l'os crestal et de l'aménagement de conditions favorables à la réorganisation optimale de l'espace biologique péri-implantaire. Dans le prolongement de cette ligne de pensée, un autre facteur, lui très récent, concerne le positionnement sous-crestal de l'épaulement de l'implant dans la mesure où ce dernier répond à certains critères plus ou moins bien définis encore à ce jour. Ce nouveau credo semble faire actuellement son chemin dans les cabinets et les congrès. On déplore cependant un discours assez « timide » et « flou » de certains fabricants d'implants ou orateurs quant à l'enfouissement idéal recommandé (ceci en fonction des caractéristiques de chaque implant). Dans cet article, nous proposons donc de nous arrêter sur ce point précis et tenterons d'exposer notre approche fondée sur la littérature disponible et sur notre pratique clinique.

Radiographie panoramique avant extraction

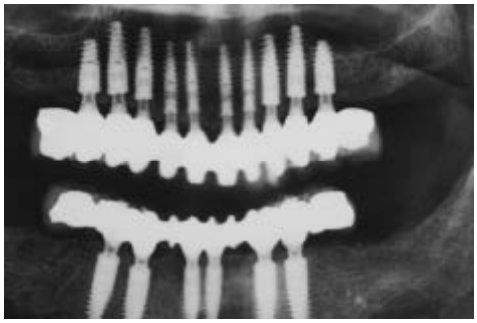

Radiographie de contrôle à 48 mois.

Mots clés : positionnement sous-crestal, table osseuse, dômes muqueux, esthétique

L'ostéotomie de Le Fort 1 au service d'une réhabilitation fixe implanto-portée

Stephan Fraisier

Le fil dentaire, 2013 ;83 :50-51

La mise en charge immédiate sur racines artificielles au maxillaire supérieur n'est pas validée par notre communauté scientifique, ni sur une fixture, ni sur plusieurs. Les échecs, lorsqu'ils surviennent sont dévastateurs, jamais publiés ni présentés, souvent oubliés. Les patients, eux, ne les oublient pas.
La chirurgie maxillo-faciale peut-être une aide précieuse pour rattraper une implantologie moderne, certes aboutie mais parfois encore imprudente.

Mots clés : ostéotomie de Le Fort, chirurgie maxillo-faciale

Mise en charge immédiate d'un bridge transvissé mandibulaire à l'aide des implants EVL®Konik
De la clinique à la réalisation prothétique – Cas clinique

Gilles Montalbot

Implant 2012 ; 18 :211-217

En préambule à cette présentation, nous concevons que la mise en charge immédiate dans le cadre des reconstructions globales implanto-portées est désormais une donnée acquise de la science.
Nous pratiquons cette technique avec un recul de 10 ans, et 67 patients traités par 395 implants (dont seulement 2 non ostéointégrés, qui ont été remplacés sans compromettre ni le bridge immédiat ni le bridge d'usage). 57 patients ont été traités à la mandibule et 10 au maxillaire supérieur, 7 patients sur les 67 ont eu une restauration bi-maxillaire. Le nombre moyen d'implants posés par cas est proche de 6 (5,89 pour être précis).
Le patient retenu pour cette présentation est Madame S, 72 ans, présentant un cas d'édentement mandibulaire sub-total compensé par un appareillage amovible inconfortable et souhaitant être traitée par la pose d'implants et la réalisation d'un bridge immédiat dans la journée. Nous allons poser des implants EVL®Konik dont la forme cylindro-conique permet une excellente stabilité primaire ce qui est particulièrement recherché en cas de mise en charge immédiate comme dans le cas présent.

Mots clés : mise en charge immédiate, bridge transvissé

Influence de la connectique cône morse dans le maintien des tissus péri-implantaires

Eric Schneck, Bernard Chapotat

Implant 2011 ;17: 203-214

Dans l'ensemble des systèmes implantaires, il existe deux systèmes de connexion à deux étages entre la suprastructure et l'implant : les systèmes à emboîtement parallèle (également appelés « à joint plat ») et les systèmes à interface conique. Ces derniers, fondés sur l'emboîtement de deux cônes normalisés, apportent une augmentation maximale de la surface de contact enre les deux pièces, ce qui évite les micromouvements et assure ainsi une plus grande stabilité de la connexion pilier-implant. Le cône morse permet aussi une meilleure répartition des contraintes et une distribution optimale des forces sur l'os péri-implantaire.

Mots clés : implant, connexion implantaire, cône morse, esthétique prothèse

Early Periimplant Tissue Healing on 1-Piece Implants With a Concave Transmucosal Design: A Histomorphometric Study in Dogs

Caroline Bolle, Marie-Paule Gustin, Didier Fau, Patrick Exbrayat, Georges Boivin, Brigitte Grosgogeat.

Implant Dent. 2015 Aug 13.

The purpose of our study was to investigate the early healing phase of marginal bone and soft tissues around unloaded 1-piece implants with a concave transmucosal design, in a dog model.
METHODS: Twenty-four 1-piece implants with a concave transmucosal neck were inserted 1 mm subcrestally in the mandibular ridge of 8 beagle dogs. Four animals were sacrificed after 3 and 12 weeks of healing. Histomorphometric analysis was performed to measure the height of the periimplant tissues.
RESULTS AND DISCUSSION: The overall height of the periimplant mucosa was, respectively, 2.67 and 2.52 mm, after 3 and 12 weeks. In the connective tissue, a soft tissue O-ring seal was observed in the healing area provided by the transmucosal concavity, after 12 weeks. The location of the first bone-to-implant contact facing the implant shoulder was 0.00 and +0.18 mm, respectively, after 3 and 12 weeks of healing. Some bone apposition occurred on the implant shoulder during the healing.
CONCLUSION: Within the limits of the present study, a concave transmucosal design in 1-piece implants was associated with a short vertical value of biological width and promoted a mechanical interlocking of the implant body at the connective tissue and marginal bone levels.

Keywords: narrow transmucosal design, biological width, histomorphometry

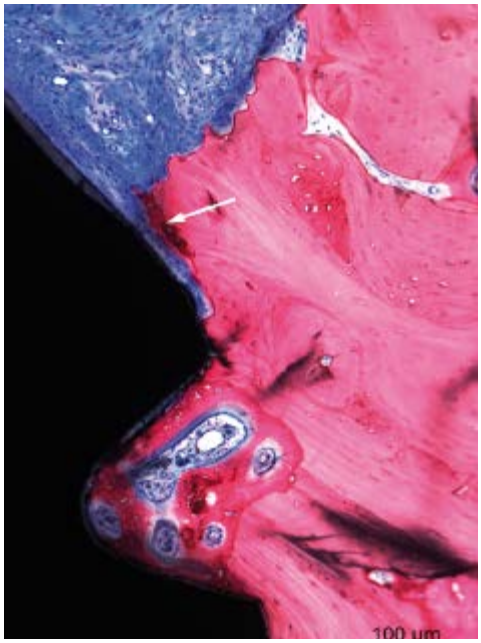

Marginal bone healing. After 3 weeks.

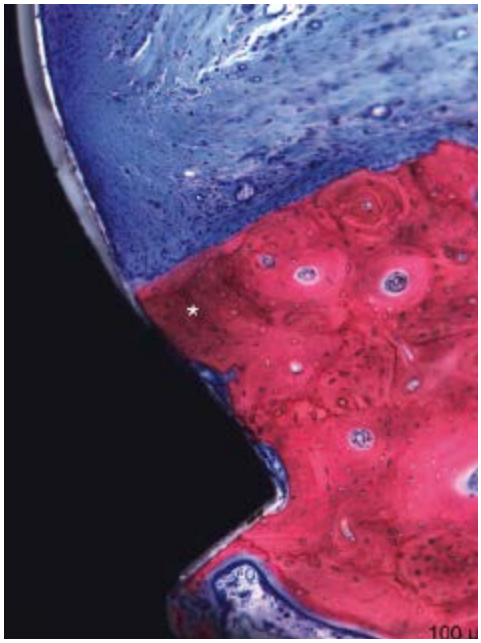

Marginal bone healing. After 12 weeks.

Posterior jaws rehabilitated with partial prostheses supported by 4.0 x 4.0 mm or by longer implants: Four-month post-loading data from a randomised controlled trial

Marco Esposito, Carlo Barausse, Roberto Pistilli, Vittorio Checchi, Michele Diazzi, Maria Rosaria Gatto, Pietro Felice

Eur J Oral Implantol. 2015

PURPOSE: To evaluate whether 4.0 x 4.0 mm dental implants could be an alternative to implants at least 8.5 mm long, which were placed in posterior jaws in the presence of adequate bone volumes.
MATERIALS AND METHODS: One hundred and fifty patients with posterior (premolar and molar areas) mandibles having at least 12.5 mm bone height above the mandibular canal or 11.5 mm bone height below the maxillary sinus, were randomised according to a parallel group design, in order to receive one to three 4.0 mm-long implants or one to three implants which were at least 8.5 mm long, at three centres. All implants had a diameter of 4.0 mm. Implants were loaded after 4 months with definitive screw-retained prostheses. Patients were followed up to 4-month post-loading and outcome measures were prosthesis and implant failures, any complications and peri-implant marginal bone level changes.
RESULTS: No patients dropped-out before the 4-month evaluation. Three patients experienced the early failures of one 4.0 mm-long implant each, in comparison to two patients who lost one long implant each (difference in proportion = 0.01; 95% CI -0.06 to 0.09; P = 0.50). Consequently, two prostheses in each group could not be delivered as planned (difference in proportion = 0; 95% CI -0.07 to 0.07; P = 0.69), and one patient from each group is still waiting to have their prostheses delivered. Three short implant patients experienced three complications versus two long implant patients (difference in proportion = 0.01; 95% CI -0.06 to 0.09; P = 0.50). There were no statistically significant differences in prosthesis failures, implant failures and complications. Patients with short implants lost on average 0.38 mm of peri-implant bone at 4 months and patients with long mandibular implants lost 0.42 mm. There were no statistically significant differences in bone level changes up to 4 months between short and long implants (mean difference = 0.04 mm; 95% CI: -0.041 to 0.117; P = 0.274).
CONCLUSIONS: Four months after loading, 4.0 x 4.0 mm implants achieved similar results as 8.5 x 4.0 mm-long or longer implants in posterior jaws, however 5 to 10 years post-loading data are necessary before reliable recommendations can be made.

Keywords: posterior jaws, short dental implants

Rehabilitation of the atrophic posterior mandible with short (4-mm) implants : a case report

Roberto Pistilli, Carlo Barausse, Luigi Checchi, Pietro Felice

Int J Periodontics Restorative Dent. 2014 Sep-Oct;34(5):713-8.

This case report describes a successful implant-prosthetic rehabilitation of an atrophic posterior mandible with 4-mm-long implants. The patient refused to undergo any reconstructive surgery, and because the available bone up to the inferior alveolar nerve was only 5 mm or less, the patient received four implants of 4-mm length. Four months after implant placement, a provisional prosthesis was put in place; after another 4 months, this was then in turn replaced with a definitive prosthesis. The use of such short implants allows a fixed prosthetic solution without the need for vertically augmenting the mandibular bone. This procedure considerably reduces intra- and postoperative patient discomfort compared with reconstructive surgery for the placement of longer implants. The follow-up time was 1 year after implant loading.

Keywords: short dental implants

Rehabilitation of an atrophic posterior mandible with 4-mm short implants: a 3 year post-loading case report

Carlo Barausse, Roberto Pistilli, Pietro Felice

Implant Dent. 2015 Aug 13.

Aim: We describe a successful implant-prosthetic rehabilitation of an atrophic posterior mandible with 4-mm long implants.

Materials and Methods:

A 62-year-old systemically healthy male was referred for fixed prosthetic rehabilitation of the right posterior mandible.Clinical and radiographic assessments showed an important posterior mandibular atrophy. Computed Tomography (CT) scans revealed 5 mm mean residual bone height above the mandibular canal.The patient refused to undergo any reconstructive surgeries, but he wanted a fixed rehabilitation, so the authors proposed placing 4-mm short transmucosal implants (TwinKon Universal SA2, Global D, Lyon, France). After local anesthesia a full-thickness crestal incision was made and 4 implants (4 mm in length and 4 mm in diameter) were placed in the mandibular right second premolar and first, second and third molar sites.

Results: The post-operative course was uneventful. Four months after implant placement, a temporary prosthesis was put in place, which was then replaced by a definitive prosthesis after another four months. The follow-up time is at three years after implants loading.

Conclusions: With the limits of this case report the use of such short implants can allow a fixed prosthetic solution without the need for vertically augmenting of the mandibular bone. This procedure considerably reduces intra and postoperative patient discomfort compared to reconstructive surgery for placing longer standard implants.

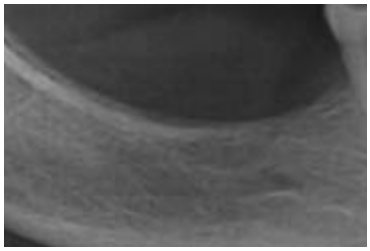

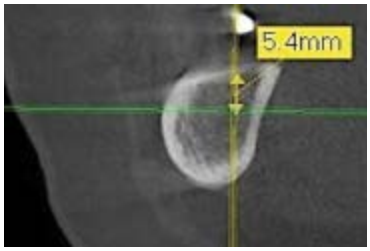

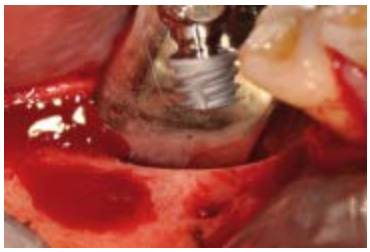

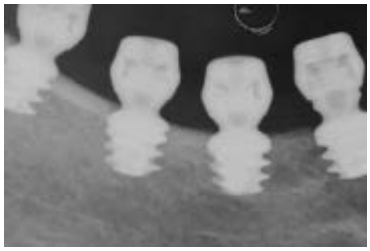

Implant placement

4 months loading

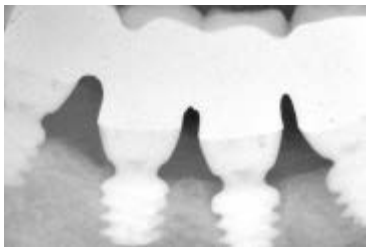

1 year loading

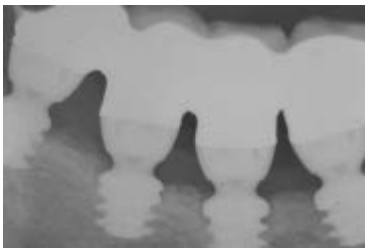

3 years loading

Domaines d'activités

Implantologie
Chirurgie pré-implantaire
Chirurgie orthognathique
Chirurgie reconstructrice
Chirurgie traumatologique de la face
Chirurgie carcinologique
Chirurgie orale
Cranio-chirurgie
Orthodontie
Formation

Global D
Partenaire de vos chirurgies

ZI de Sacuny - BP 82
118 avenue Marcel Mérieux
69530 Brignais
France

tél. +33 (0)4 78 56 97 00
fax +33 (0)4 78 56 01 63

www.globald.com

Une société du groupe MENIX

0DDC-CB-FR-Ed1-16